


Diagnostic and Therapeutic Hysteroscopy Course



UniversitätsSpital
Zürich



Description

Simbionix and VirtaMed have joined forces to provide OB/GYN surgeons with the most comprehensive training system available for diagnostic and therapeutic hysteroscopy. A study by Bajka et al [1] has shown that the HystSim™ simulator provides highly realistic and useful training for hysteroscopic surgery, with high acceptance ratings for both experienced and novice surgeons.

The VirtaMed HystSim™ is a virtual reality simulator for newly qualified surgeons. It offers training in diagnostic and therapeutic hysteroscopy. This program has been integrated into a specially developed curriculum at Zurich University Hospital. Following the latest principles in education and hands-on training, surgeons obtain all-embracing practical skills ("best practice") to operate successfully in gynecology.

The main focus of the course is the training of important and frequent interventions. In a true-to-life environment using original instruments, surgeons can gather realistic hands-on-experience by working on various pathologies and encountering complications such as strong bleedings or perforation. The necessary basic skills are acquired without any risk for the patient, and even experienced gynecologists can perfect their competence on a variety of virtual patients with different pathologies which they might

not have encountered yet during their career. The theoretical background is built into the HystSim™ to teach the correct practical approach.

Objective performance feedback supports and completes the learning process in showing individually and targeted areas of improvement. Two recent studies have shown that training on the HystSim™ in a realistic environment provides the ideal preparation for interventions on live patients, and that a substantial part of the personal learning curve can be completed on the simulator (Bajka et al. 2008, 2009). The graduates of this course cover an important part of their personal learning curve before taking this knowledge to the operating room. During this program the participants are the ones who determine their learning path and speed. Two trainees team up to work on the simulator, while experienced instructors accompany and guide them during the entire course.

This training course was designed by PD Dr. Michael Bajka, MD, University Hospital Zurich, Switzerland.

Objectives

- ◆ To perform a safe and effective diagnostic hysteroscopy.
- ◆ To perform ideal navigation with the angled optics (mainly 30°).
- ◆ To control fluid for a clear view.
- ◆ To handle the resectoscope ergonomically.
- ◆ To practice safe and efficient resection of polyps and myomas with the loop.
- ◆ To securely coagulate bleeders.
- ◆ To practice elaborate operative strategies.
- ◆ To handle problems and complications.
- ◆ To perform rollerball endometrial ablation.

Specialties

- ◆ Gynecology.

Target Audience

The basic course is of greatest benefit for gynecologists in their first to third year of studies or for experienced gynecologists who want to gain first experience in the field of endoscopic surgery.

Assumptions

No previous procedural or technical knowledge is required.

Suggested Time Length

Course participants are required to complete the course within a time frame of 3-4 months.

Authors

This training program was designed by PD Dr. Michael Bajka, MD, University Hospital Zurich, Switzerland.

Introduction to Course – Instructors

Course Introduction

The course begins with an introduction day where the participants first learn how to use the HystSim™. In addition, the goals of the course are outlined.

1. Introduction to the Practical Approach – 2 hour

The participants will be introduced to the practical aspects of the following tasks, on which they will work at a later stage on the simulator, always under professional guidance:

- ◆ Ideal navigation with the angled optics (mainly 30°)
- ◆ Fluid control for a clear view
- ◆ Ergonomic handling of the resectoscope
- ◆ Resection of polyps and myoma with the loop
- ◆ Endometrium ablation with the rollerball
- ◆ Secure coagulation of bleeders
- ◆ Elaborate operative strategies
- ◆ Problems and complications handling
- ◆ Personal feedback and advice on improving the techniques

Introduction to Hands-On-Training

The practical part of the training offers hysteroscopic interventions on the HystSim™ in many different aspects. The participants can train extensively on a large variety of virtual patients, starting with purely diagnostic hysteroscopy up to complex operative hysteroscopy.

2. Independent Hands-On-Training – 1 month

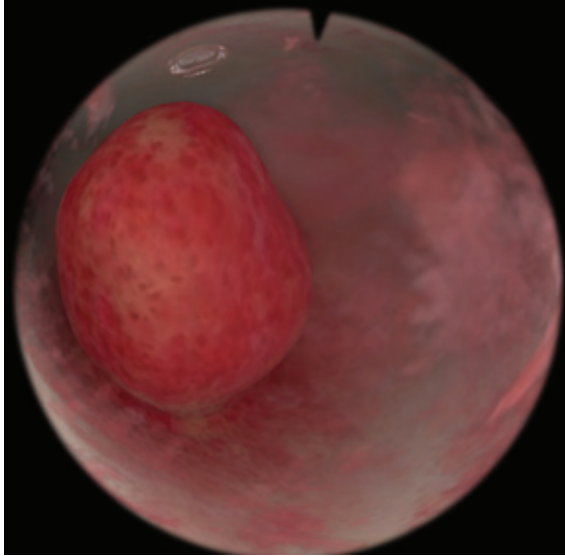
In general, a minimum number of training sessions is required to finish the course (about 12-18 hours of training, depending on trainee). Some of them can be accompanied during individual training sessions, others can be done alone. A fixed training plan is set, with an escalating level of difficulty. After the course, the participant will have performed up to 100 hysteroscopic interventions.

1 month of independent training, with the simulator being at the trainees' disposal 24/7.

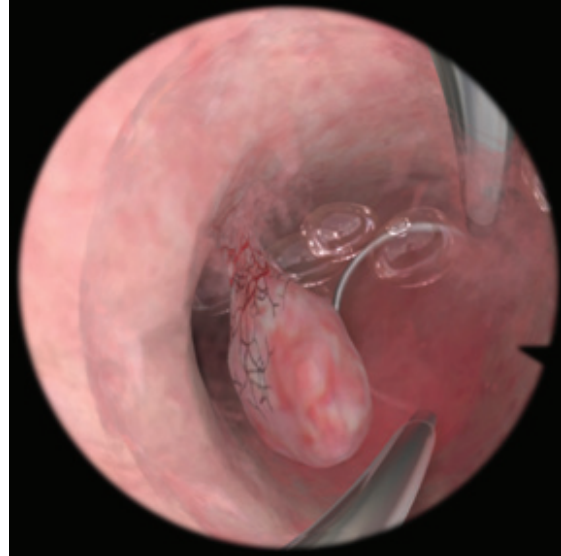
3. Conclusion and Exam

The data will be analyzed, evaluated and presented to the participant during a final meeting. The course is to be completed within 3-4 months. The final meeting may include 2 hours of intensive training and an exam, performing complicated cases on the HystSim.

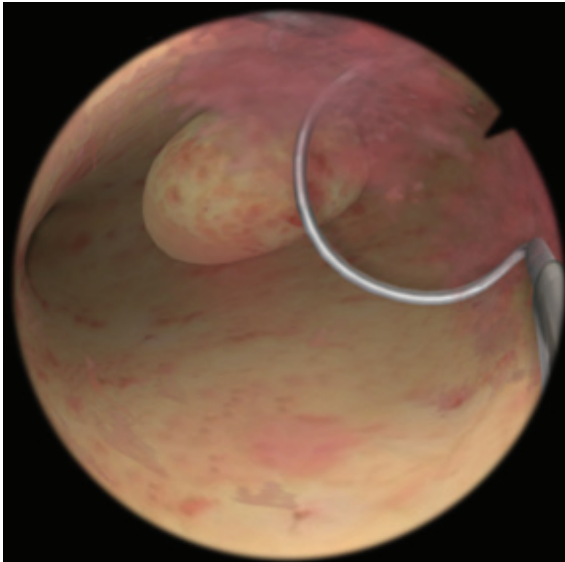
The required performance level is at least 90% for each patient case.



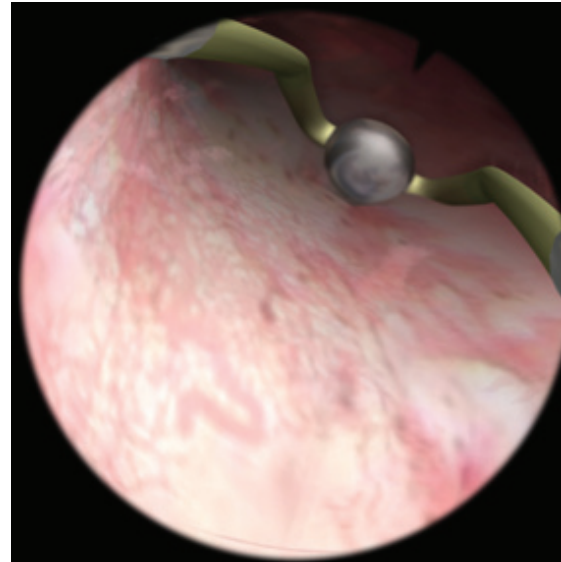
Diagnostic Hysteroscopy



Diagnostic Hysteroscopy



Myoma Resection



Rollerball Endometrial Ablation

Expert Opinions




Prof. Dr. Daniel Fink, Director Hospital for Gynaecology, University Hospital Zurich

"VirtaMed HystSim is clearly the most realistic simulator for hysteroscopy on the market today - it even allows the training of complication scenarios. I recommend it to all our residents before they perform their first cases in the OR."

Acknowledgements

This training program was designed by PD Dr. Michael Bajka, MD, University Hospital Zurich, Switzerland. University Hospital Zurich has become the “home base” of VirtaMed. A decade ago the fruitful collaboration started, and the medical input from practicing surgeons has been very useful in every phase of Research & Development. The most recent collaboration has been the testing of this training program.
<http://www.en.usz.ch/Pages/default.aspx>



PD Dr. Michael Bajka, MD (in the center), at the Diagnostic and Therapeutic Hysteroscopy Course, University Hospital Zurich, Switzerland

Task Descriptions and Training Curriculum Steps

The trainee is required to follow a structured step by step curriculum defined in a hierarchical order in the following manner:

1. Introduction to the Practical Approach – 2 hours

At the beginning of this teaching block the participants will be introduced to the practical aspects of the following tasks, which they will work on at a later stage on the simulator, always under professional guidance:

Learning Objectives:

- ◆ Ideal navigation with the angled optics (mainly 30°)
- ◆ Fluid control for a clear view
- ◆ Ergonomic handling of the resectoscope
- ◆ Resection of polyps and myoma with the loop
- ◆ Endometrium ablation with the rollerball
- ◆ Secure coagulation of bleeders
- ◆ Elaborate operative strategies
- ◆ Problems and complications handling
- ◆ Personal feedback and advice on improving the techniques

2. Diagnostic hysteroscopy

Diagnostic hysteroscopy is the fundamental start of every hysteroscopic intervention. Only if it is implemented correctly, the participant may continue to the following procedures.

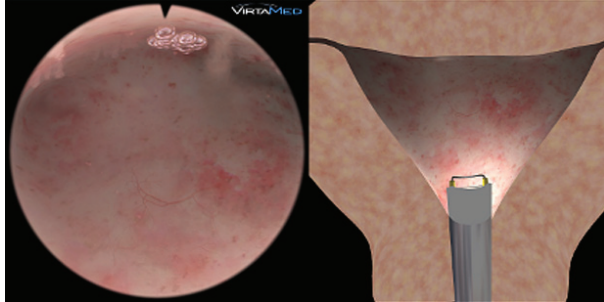
The module includes 12 virtual patients with varying pathologies and different levels of difficulty. At the beginning, the simulator takes over some of the functions so that the trainee can focus on a specific element of the procedure.

The trainee gains experience in using the angled optics or in establishing a clear and defined view and learns how to visualize the entire cavity in a safe environment.

A performance overview after each intervention provides detailed feedback on the visualized inner surface, the efficiency of the approach (procedure time, camera path, etc.) and safety aspects (collisions of the hysteroscope with the wall provoking injuries, cervix contacts, etc.) as well as feedback on instrument handling.

Instructions:

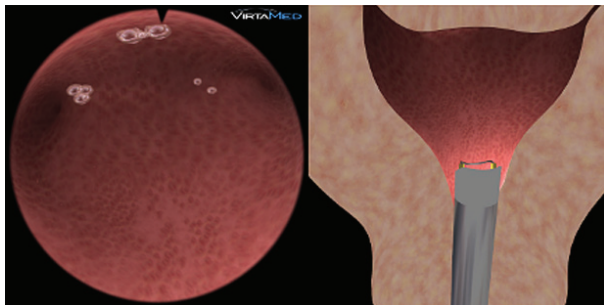
- ◆ Create enough work space (Cavity distention)
- ◆ Establish clear viewing conditions
- ◆ Confirm correct placement of hysteroscope via identifying right and left tubal ostia (Safety)
- ◆ Complete visualization of the whole inner surface (Visualization)
- ◆ Efficient camera handling
- ◆ Avoid touching the wall (Safety)
- ◆ Describe the shape of the uterus and all pathologies (Diagnosis)
- ◆ Analyze the scoring (Debriefing)
- ◆ Define personal objectives for improvement (My goals)



Diagnosics Easy 1

Task Description:

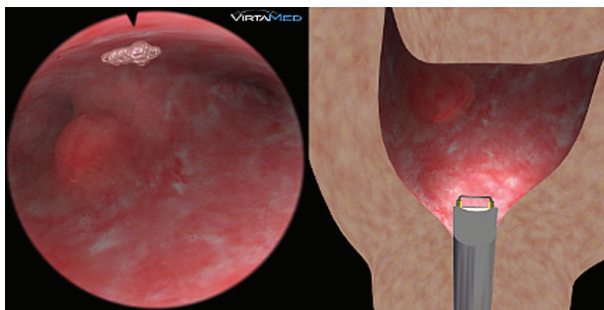
- ◆ Normal shaped cavity, parous woman
- ◆ No pathology
- ◆ No bleeding



Diagnosics Easy 2

Task Description:

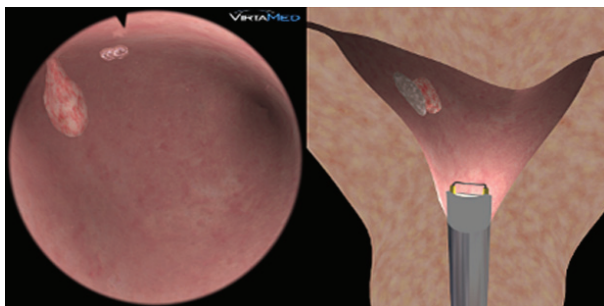
- ◆ Arcuate uterus, parous woman
- ◆ No pathology
- ◆ No bleeding



Diagnosics Easy 3

Task Description:

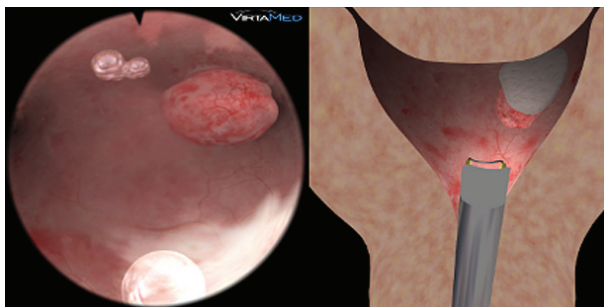
- ◆ Spheric cavity with asymmetric tubal angles, parous woman, little bleeding
- ◆ Small myoma close to the right fallopian tube at the fundus



Diagnosics Easy 4

Task Description:

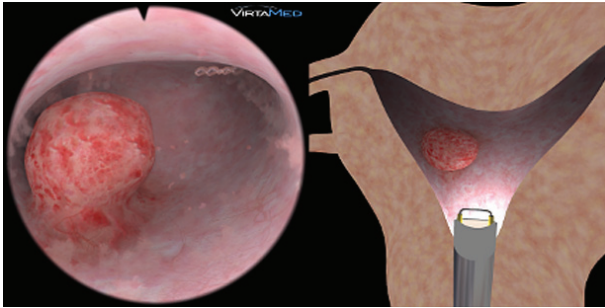
- ◆ Bicornue uterus with asymmetric tubal angles
- ◆ Small pedunculated polyp in front of the right fallopian tube at the anterior wall
- ◆ Little bleeding



Diagnosics Medium 1

Task Description:

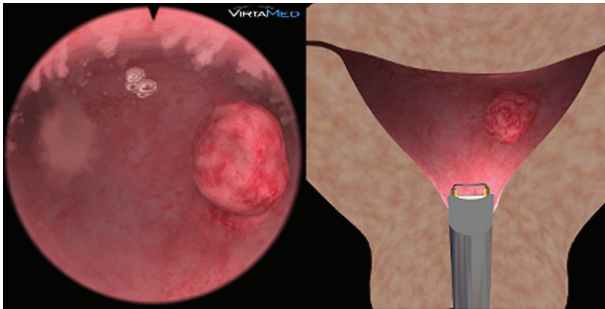
- ◆ Arcuate uterus, symmetric tubal angles
- ◆ Medium-sized myoma in the fundus/anterior wall close to the left fallopian tube
- ◆ Fluffy tissue, little bleeding



Diagnostics Medium 2

Task Description:

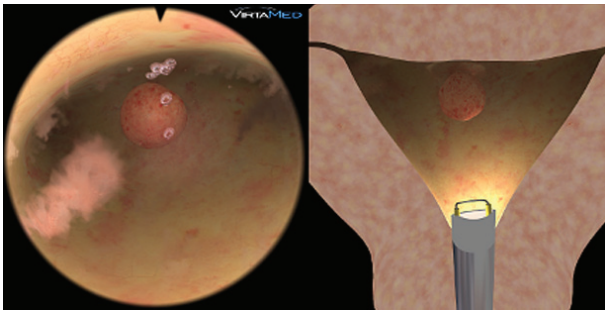
- ◆ Bicornue uterus, asymmetric tubal angles
- ◆ Medium-sized myoma in the right part of the uterus
- ◆ Fluffy tissue, little bleeding



Diagnostics Medium 3

Task Description:

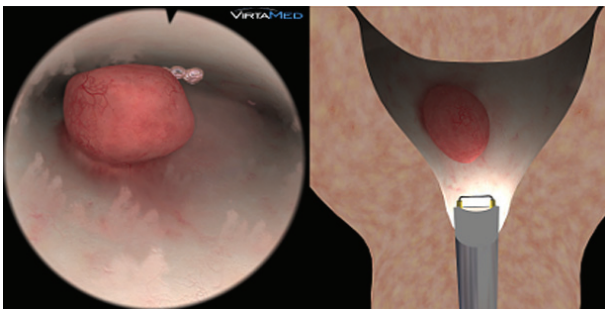
- ◆ Normal cavity, deep symmetric tubal angles
- ◆ Larger myoma blocking the right fallopian tube
- ◆ Floating tissue, fluffy, little bleeding



Diagnostics Medium 4

Task Description:

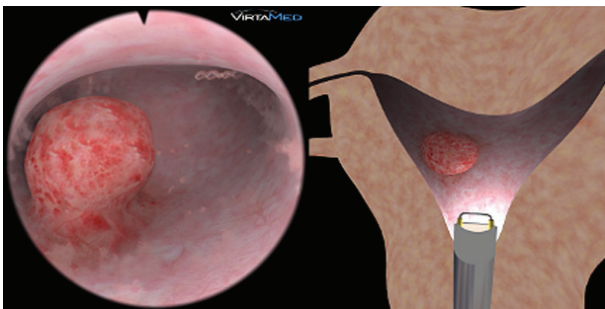
- ◆ Normal shaped uterus
- ◆ Small myoma at the fundus
- ◆ Little bleeding when entering the right ostia
- ◆ Few fluffy tissue parts



Diagnostics Difficult 1

Task Description:

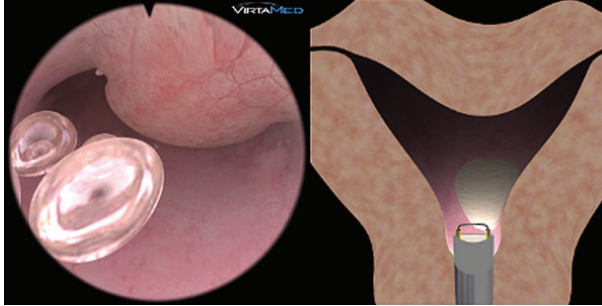
- ◆ Narrow, tight uterus
- ◆ Larger myoma centered in the uterus, on the posterior wall
- ◆ Medium bleeding



Diagnostics Difficult 2

Task Description:

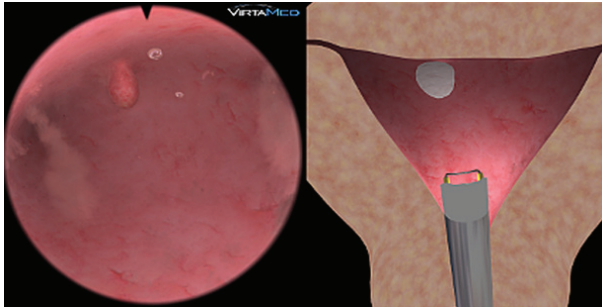
- ◆ Normal shaped uterus
- ◆ Stronger bleeding, fluffy tissue
- ◆ Medium-sized myoma partially closing the cervix
- ◆ Second, smaller fibroid hidden behind the other one



Diagnostics Difficult 3

Task Description:

- ◆ Arcuate uterus
- ◆ Large myoma at the anterior wall partially blocking the entry from the cervical canal into the uterus
- ◆ Stronger bleeding, difficult entry



Diagnostics Difficult 4

Task Description:

- ◆ Normal shaped uterus
- ◆ Small polyp located close to the fundus at the anterior wall
- ◆ Floating tissue parts, fluffy, stronger bleedings

3. Polyp Resection

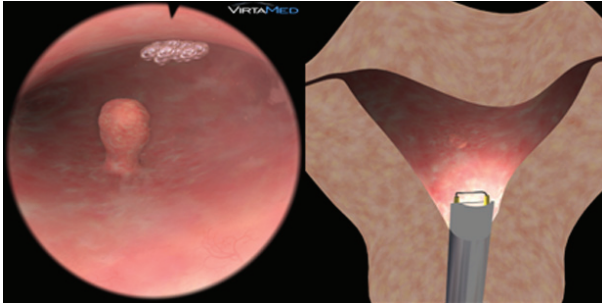
A uterine polyp is an endometrial lesion taking up space within the uterine cavity. It can be a large, elongated pathology which consists of rather soft tissue. A hysteroscopic treatment is clearly to be preferred to a blind curettage.

This first module on operative hysteroscopy offers 8 virtual patients with various polyps of different sizes and in different positions. It aims at providing training for the first steps in working with the loop electrode.

In addition to the diagnostic aspects, the performance review also provides feedback on the amount of the polyp removed, the efficiency of the procedure and safety aspects (resecting with electricity).

Practical approach and objectives

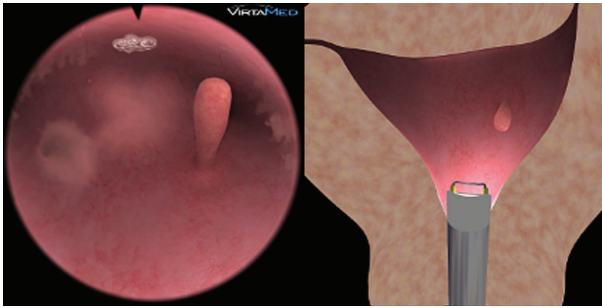
- ◆ Inspect the cavity completely and describe visible pathologies
- ◆ Use the electrical loop safely: CUT ONLY WHILE RETRACTING THE LOOP, NEVER WHILE PUSHING!
- ◆ Establish clear viewing conditions
- ◆ Correct technique for polyp resection
- ◆ If the polyp is not larger than the hysteroscopic sheath, try to cut the stalk directly
- ◆ If the polyp is larger than the hysteroscopic sheath, cut it into chips
- ◆ Remove the stalk completely, while preserving the healthy tissue
- ◆ Remove the resected pieces from the cavity
- ◆ Note fluid loss/balance and resection time (Safety)
- ◆ Analyze the scoring (Debriefing)
- ◆ Define personal objectives for improvement (My goals)



Polypectomy Easy 1

Task Description:

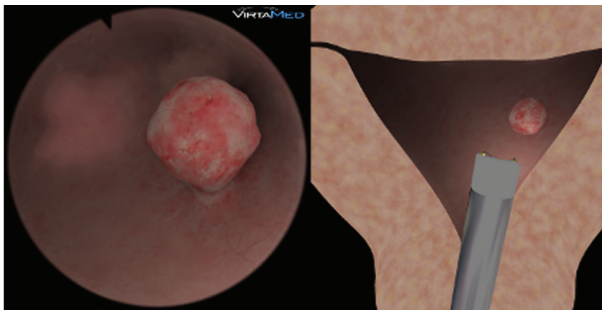
- ◆ Arcuate uterus
- ◆ Small polyp on the right posterior wall
- ◆ Few fluffy tissue parts



Polypectomy Easy 2

Task Description:

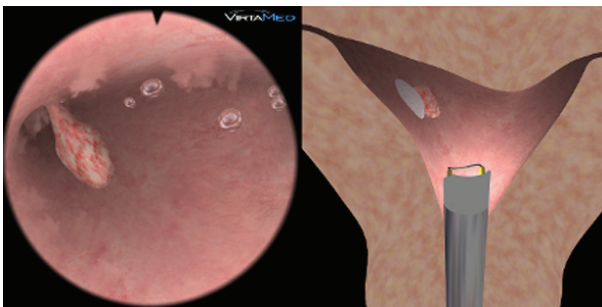
- ◆ Arcuate uterus
- ◆ Pedunculated polyp with a narrow, elongated stalk located on the back/posterior left wall
- ◆ Fluffy tissue texture



Polypectomy Easy 3

Task Description:

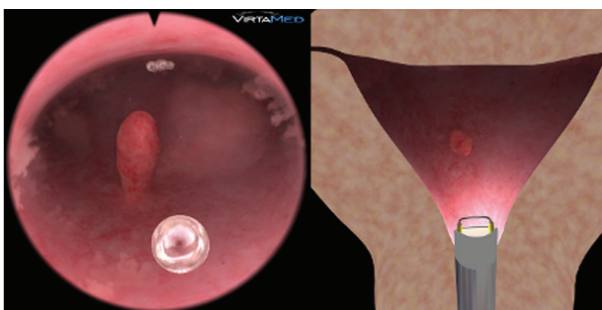
- ◆ Normal shaped uterus
- ◆ Medium-sized polyp in front of the left fallopian tube



Polypectomy Easy 4

Task Description:

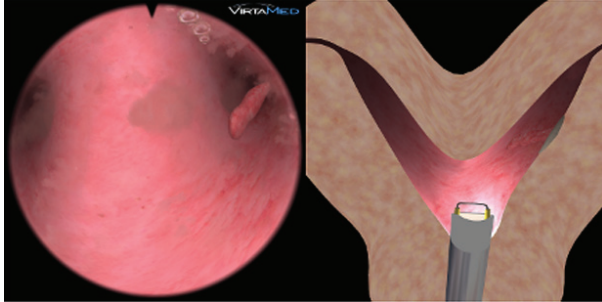
- ◆ Bicornue uterus, asymmetric tubal angles
- ◆ Small polyp blocking the right fallopian tube, attached to the anterior wall
- ◆ Some floating tissue parts



Polypectomy Medium 1

Task Description:

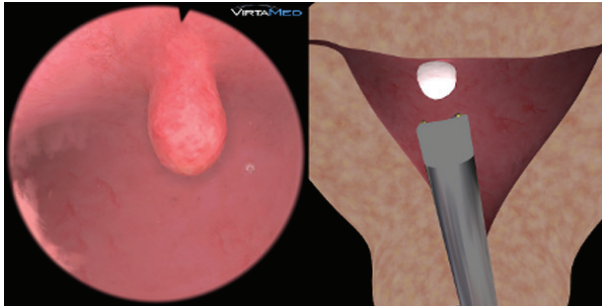
- ◆ Normal shaped uterus
- ◆ Pedunculated small polyp located in the center of the uterus, attached to the posterior wall
- ◆ Fluffy tissue



Polypectomy Medium 2

Task Description:

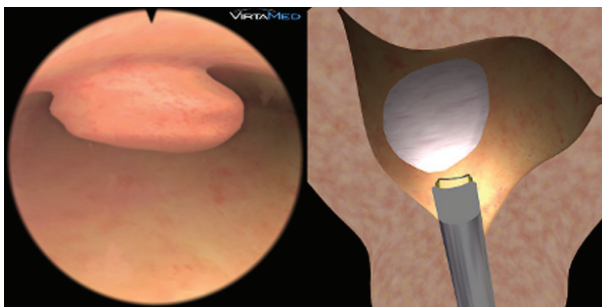
- ◆ Bicornuate, symmetric uterus
- ◆ Small, narrow and elongated pedunculated polyp inside of the left fallopian tube
- ◆ Some tissue parts floating in the uterus



Polypectomy Medium 3

Task Description:

- ◆ Normal shaped uterus
- ◆ Medium-sized, sessile polyp with a broad base close to the fundus, in anterior position
- ◆ Almost clear view



Polypectomy Medium 4

Task Description:

- ◆ Heavily distorted cavity, parous woman
- ◆ Large sessile polyp with a broad base blocking the right tubal opening, attached to the anterior wall
- ◆ Fluffy tissue

4. Myoma Resection

Myoma are various sized, hard, mostly well distinguishable tumors, which are located in or on the uterine wall. Submucosal fibroids (type 0, I, II) can be treated hysteroscopically. Type 0 Myoma (intracavitary myoma) and type I myoma (<50% inside the uterine wall) should be removed completely. Type II myoma (>50% inside the uterine wall) should only be partially resected until they reach the level of the myometrium, NOT DEEPER! The rest of the myoma should be removed at a later stage in a second operation.

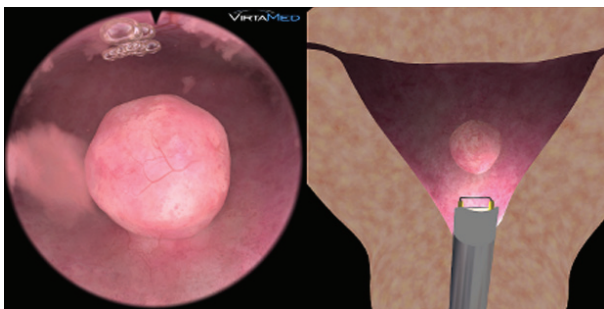
The module includes 8 virtual patients with varying types of submucosal fibroids (type 0 and type I) in different positions and with different levels of difficulties.

The performance review provides feedback on the amount of the pathology removed and on the quality and safety of the resection.

Practical approach and objectives

- ◆ Perform a complete diagnostic hysteroscopy
- ◆ Use the electrical loop safely: CUT ONLY WHILE RETRACTING THE LOOP, NEVER WHILE PUSHING!
- ◆ Establish clear viewing conditions
- ◆ Correct technique for myoma resection:
- ◆ Cutting the myoma into small chips

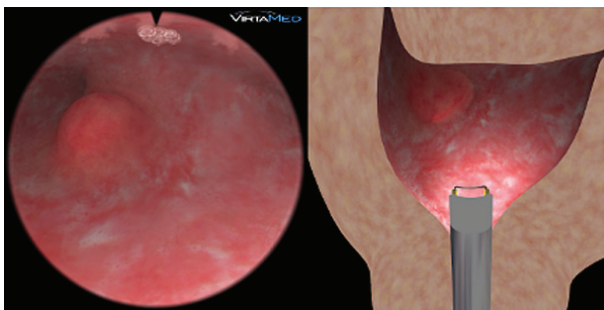
- ◆ No resection into the wall of the uterine cavity
- ◆ Remove the stalk completely, while preserving the healthy tissue
- ◆ Remove the resected pieces from the cavity
- ◆ Perform a control hysteroscopy at the end
- ◆ Note fluid loss/balance and resection time (Safety)
- ◆ Analyze the scoring (Debriefing)
- ◆ Define personal objectives for improvement (My goals)
- ◆ Define personal objectives for improvement (My goals)



Myomectomy Medium 1

Task Description:

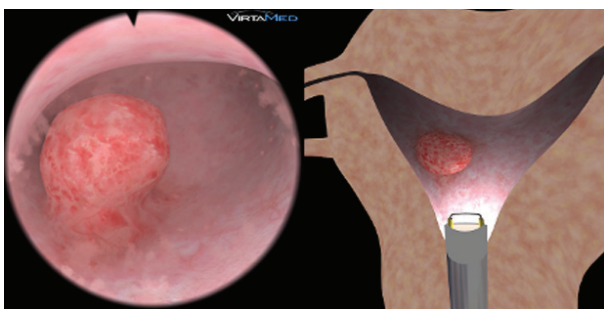
- ◆ Normal shaped uterus
- ◆ Myoma centered in the uterus
- ◆ Tissue a little bit fluffy



Myomectomy Medium 2

Task Description:

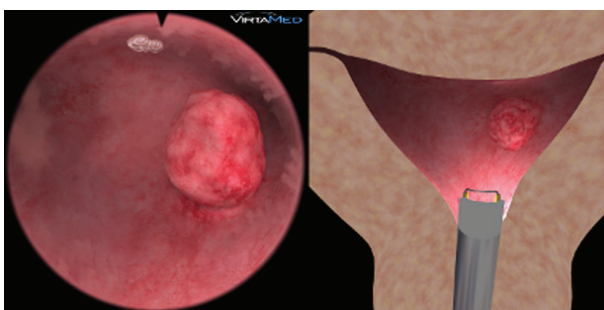
- ◆ Spheric cavity with asymmetric tubal angles, parous women, little bleeding
- ◆ Small myoma close to the right fallopian tube at the fundus



Myomectomy Medium 3

Task Description:

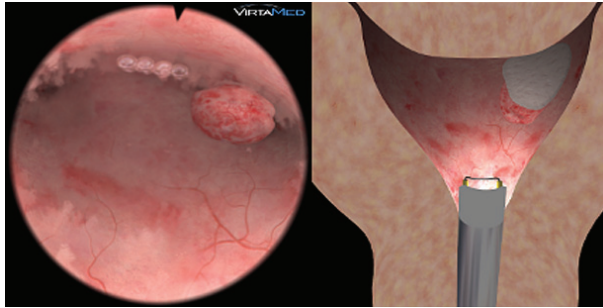
- ◆ Bicornue uterus, asymmetric tubal angles
- ◆ Medium-sized myoma in the right part of the uterus
- ◆ Fluffy tissue, little bleeding



Myomectomy Medium 4

Task Description:

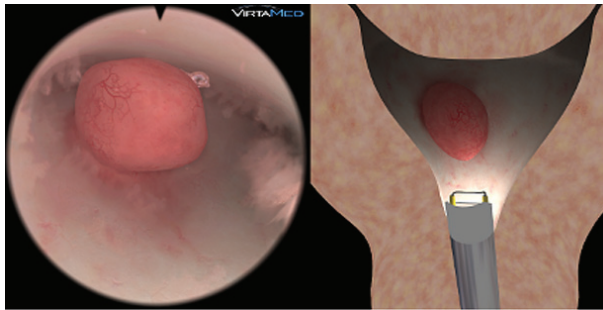
- ◆ Normal shaped uterus
- ◆ Pedunculated small polyp located in the center of the uterus, attached to the posterior wall
- ◆ Fluffy tissue



Myomectomy Difficult 1

Task Description:

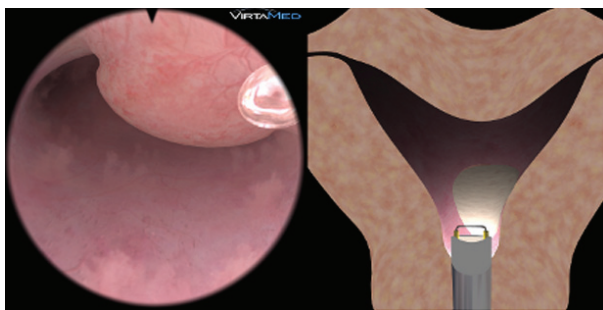
- ◆ Arcuate uterus, symmetric tubal angles
- ◆ Medium-sized myoma in the fundus/anterior wall close to the left fallopian tube
- ◆ Fluffy tissue, little bleeding



Myomectomy Difficult 2

Task Description:

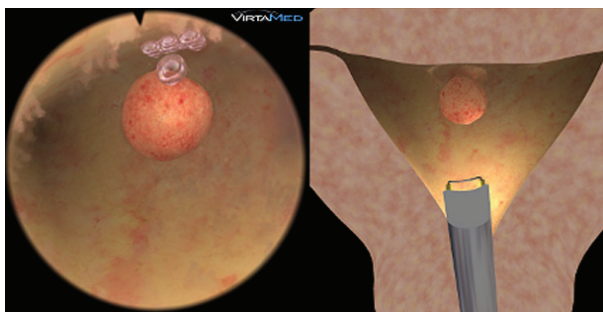
- ◆ Narrow, tight uterus
- ◆ Larger myoma centered in the uterus, on the posterior wall
- ◆ Medium bleeding



Myomectomy Difficult 3

Task Description:

- ◆ Arcuate uterus
- ◆ Large myoma at anterior wall partially blocking entry from cervical canal into the uterus
- ◆ Stronger bleeding, difficult entry



Myomectomy Difficult 4

Task Description:

- ◆ Normal shaped uterus
- ◆ Small myoma at the fundus
- ◆ Little bleeding when entering the right ostia
- ◆ Few fluffy tissue parts

5. Rollerball Endometrial Ablation

Endometrium ablation with the rollerball remains the gold standard for the permanent treatment of abnormal uterine bleeding when the family doesn't want additional children. Nevertheless, it is not deemed a reliable measure for contraception. It is conducted as a single measure or combined with other contraceptive means.

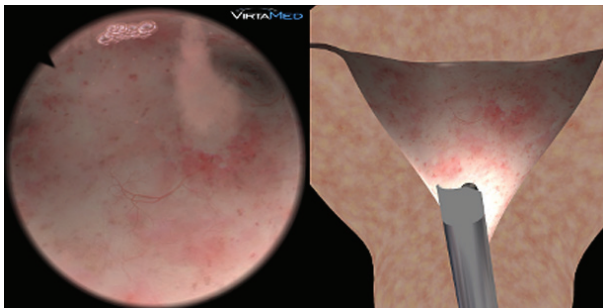
Endometrium ablation with the rollerball is an ideal exercise to gain practice in all important maneuvers to get used to the correct handling of the resectoscope. Thanks to the broad contact area of the rollerball with the surface, this happens with very low risk of perforation.

The module contains 4 different virtual patients with varying shapes of uterine cavities.

In addition to the general aspects, performance review provides feedback on the coagulated uterine surface, economy (procedure time, camera path) and safety measures.

Practical approach and objectives

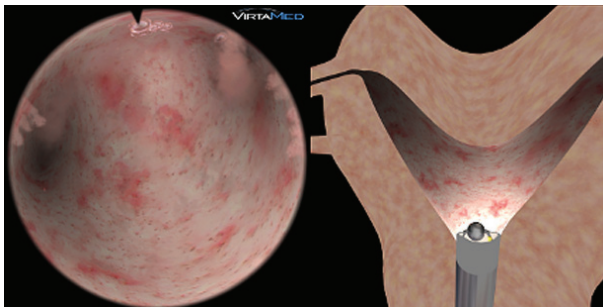
- ◆ Perform a complete diagnostic hysteroscopy
- ◆ Establish clear viewing conditions
- ◆ Practice the correct technique for endometrium ablation:
 - Use the rollerball systematically
 - Take long strokes staying in permanent contact with the endometrium
 - Coagulate the entire surface
- ◆ Caution in the area of the tubal ostia and the inner cervical os
- ◆ Perform a control hysteroscopy at the end
- ◆ Note fluid loss/balance and procedure time (Safety)
- ◆ Analyze the scoring (Debriefing)
- ◆ Define personal objectives for improvement (My goals)



Endometrium Ablation Medium 1

Task Description:

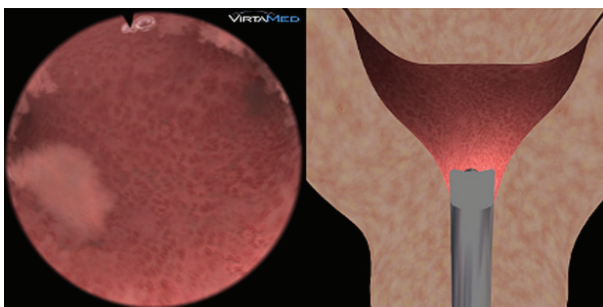
- ◆ Normal shaped uterus
- ◆ No bleeding
- ◆ Easy access



Endometrium Ablation Medium 2

Task Description:

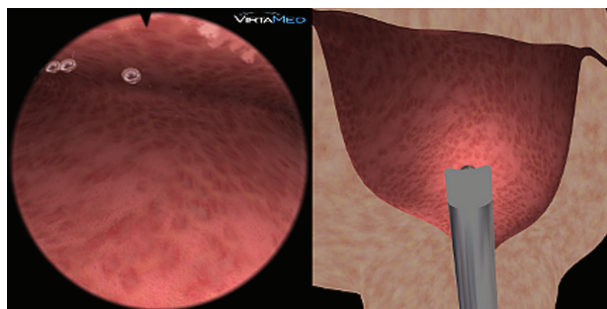
- ◆ Bicornuate uterus
- ◆ No bleeding
- ◆ Little bit fluffy tissue



Endometrium Ablation Medium 3

Task Description:

- ◆ Arcuate uterus with symmetric deep tubal angles
- ◆ No bleeding
- ◆ Floating tissue parts, very fluffy



Endometrium Ablation Medium 4

Task Description:

- ◆ Spheric cavity, multiparous woman
- ◆ Very narrow, tight uterus
- ◆ Some fluffy tissue parts

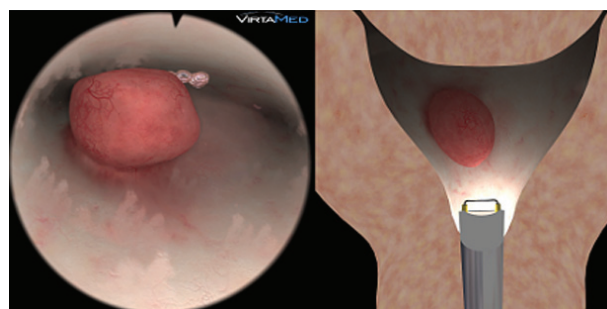
1. Conclusion and Exam

Perform complicated cases, example cases are selected below.

The data will be analyzed, evaluated and presented to the participant during a final meeting.

Required Skill Level:

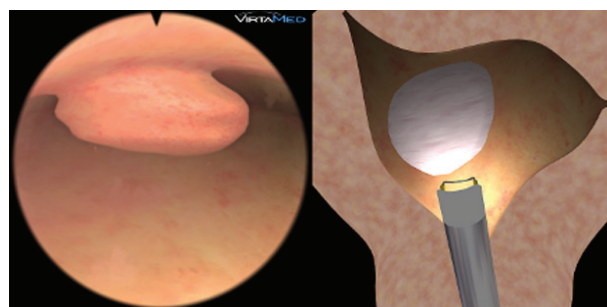
The trainee needs to be able to perform a complete diagnostic procedure, safely handle the resectoscope, correctly work with the camera and control the fluid with in- and outvalve, and safely resect the pathologies.



Diagnostics Difficult 1

Task Description:

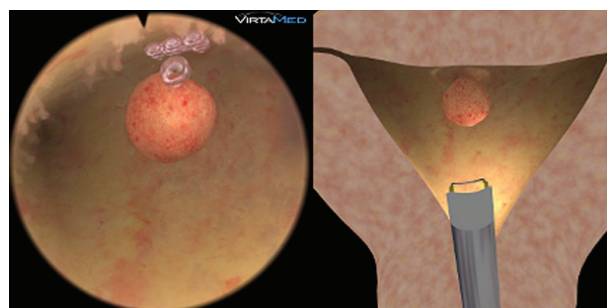
- ◆ Narrow, tight uterus
- ◆ Larger myoma centered in the uterus, on the posterior wall
- ◆ Medium bleeding



Polypectomy Medium 4

Task Description:

- ◆ Heavily distorted cavity, parous woman
- ◆ Large sessile polyp with a broad base blocking the right tube, attached to anterior wall
- ◆ Fluffy tissue



Myomectomy Difficult 4

Task Description:

- ◆ Normal shaped uterus
- ◆ Small myoma at the fundus
- ◆ Little bleeding when entering the right ostia
- ◆ Few fluffy tissue parts

References

1. "Evaluation of a new virtual-reality training simulator for hysteroscopy". Bajka et al. Surgical Endoscopy. 2008.
2. "Preliminary Experience with Virtual Reality Simulation vs. Animal Model for Hysteroscopic Myomectomy Training". Glazerman et al. The Journal of Minimally Invasive Gynecology. November 2009.

Disclaimer

Surgery should be performed only by licensed surgeons who have developed adequate skills and received specific training to perform the tasks associated with each procedure. Symbionix educational products are focused on specific skills and are not meant to teach surgery. Symbionix educational products do not replace the necessary medical training and experience required to perform surgery.

Simulated training models may significantly differ from real life behavior.

Symbionix makes no claims as to the competency, training or licensing of physicians.